

Automated Exudates Detection and Grading of Diabetic Maculopathy in Digital Retinal Images

Thangalapally Soujanya

M.Tech(ES),

Kshatriya College of Engineering.

K.Gopal, M.E(DSE)

Assistant Professor,

Kshatriya College of Engineering.

Abstract:

Diabetic macular edema (DME) is a common vision threatening complication of diabetic retinopathy which can be assessed by detecting exudates (a type of bright lesion) in fundus images. Diabetes mellitus is a major cause of visual impairment and blindness. Twenty years after the onset of diabetes, almost all patients with type1 diabetes and over 60% of patients with type2 diabetes will have some degree of retinopathy. Prolonged diabetes retinopathy leads to maculopathy, which impairs the normal vision depending on the severity of damage of the macula. In this work, we present a computer-based intelligent system based on mathematical morphology for detecting exudates in color eye fundus images and identification of clinically significant, non-clinically significant maculopathy and normal fundus eye images. Features are extracted from these raw fundus images using morphological image processing techniques, which are then fed to the classifier. Our protocol uses feed-forward architecture in an artificial neural network classifier for classification of different stages. Three different kinds of eye disease conditions were tested in 350 subjects. We demonstrated a sensitivity of more than 95% for these classifiers with a specificity of 100%, and results are very promising. Our systems are ready to run clinically on large amounts of datasets.

1. Introduction:

Medical image analysis is a research area that has recently attracted intense interest among scientists and physicians. It consists of the study of digital images with the objective of providing computational tools that help quantify and visualize interesting pathologies and anatomical structures.

The progress achieved in this area over recent years has significantly improved the type of medical care that is available to patients. Physicians can now examine inside the human body to diagnose, treat, monitor changes and plan different treatments more successfully than previously. The physician can thus obtain decision support, be reassured of repetitive tasks, and consistently receive valuable measurements. However, this is a multi disciplinary task and requires comprehensive knowledge in many disciplines, such as image processing and computer vision, machine learning, pattern recognition and systems. The severe progression of diabetes is one of the great challenges to the current health care. The number of people afflicted continues to grow at an alarming rate. The World Health Organization expects the number of diabetics to increase from 130 million to 350 million over the next 25 years. However, only half of the patients are aware of the disease. Diabetes leads to severe late complications including macro and micro vascular changes resulting in heart disease and retinopathy. Diabetic retinopathy (DR) is a common complication of diabetes and the leading cause of blindness in the working population of western countries. It is a silent disease and may only be recognized by the patient when the changes in the retina have progressed to a level where treatment is complicated and nearly impossible. The prevalence of retinopathy varies with the age of onset of diabetes and the duration of the disease in younger patients (below 30 years of age) is minimal during the first 5 years but increases to greater than 95% after 15 years of diabetes.

1.1 Structure of the normal human eye:

The eye works like a camera. Light rays reflected by objects enter the eye through the cornea, which acts like a window in the white of the eye and provides the focusing power. The cornea is the principal lens of the eye and is the site where refractive surgery is conducted. Light travels through the pupil or black circle of the iris (the colored part of the eye). The main function of the iris is to control the quantity of light entering the eye by either becoming smaller in size in bright light or larger in dim light. Light then travels through the lens. The function of the lens is to adjust the focus for near vision. The retina acts as the film in the camera; it is a membrane that covers the back of the eye. The images that we see are focused and then the information is carried by the optic nerve to the brain.

The brain, upon reception of these signals interprets the images and objects seen by the eye. Figure 1(a) shows a cross section of the human eye. The macula is the most sensitive part of the retina and is responsible for vision. It is located near the optic nerve directly at the back of the eye (on the inside). This area is also responsible for color vision. The optic disc (or optic nerve head) is the entry and exit site of blood vessels and optic nerve fibers from the retina to the optic nerve. The optic nerve transmits electrical impulses from the retina to the brain. It is a brighter region than the rest of the ocular fundus and its shape is usually round. The optic disc is approximately 3 mm nasal to the fovea, and measures about 1.5 – 2 mm in diameter. The optic disc contains a central depression called the optic cup and its depth varies from individual to individual.

Figure 1(b) illustrates atypical normal fundus image with highlighted regions of macula, fovea and optic disc components. The macula or central area has the following components from the center to the periphery: Fovea, Parafovea and Perifovea, as shown in figure 2. Figure 3(a) shows a fundus image of the normal eye.

Diabetes can affect the eye in a number of ways. The most serious eye condition associated with diabetes, diabetic retinopathy, involves the retina, and, more specifically, the network of blood vessels lying within it. Diabetic retinopathy is usually graded according to its severity. This condition is very common in people who have had diabetes for a long time. The vision may be normal with no threat to the sight. At this stage the blood vessels in the retina are only very mildly affected and they may bulge slightly (micro aneurysm) and may leak blood or fluid (exudates). The macula area of the retina mentioned earlier remains unaffected. With time, if the background diabetic retinopathy becomes more severe, the macula area may become involved. This is called maculopathy. In diabetic maculopathy, fluid rich in fat and cholesterol leaks out of damaged vessels. If the fluid accumulates near the center of the retina (the macula), there will be distortion of central vision. If too much fluid and cholesterol accumulates in the macula, it can cause permanent loss of central vision. Non-clinically significant maculopathy and clinically significant maculopathy are the two types of the maculopathy eye disease.

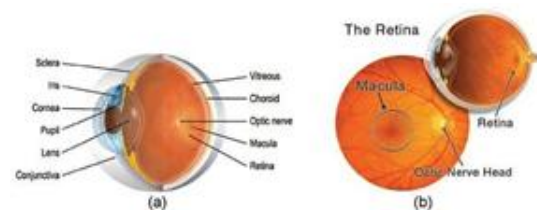


Figure 1. Structure of (a) the human eye and (b) the human retina.

2. Non-clinically significant maculopathy (Non-CSME):

Figure 3(b) shows a non-CSME fundus image, where there are no visible symptoms, so patients may not realize they are affected. Exudates start to leak out from the damaged vessels which result from diabetes and areas of leakage develop in the retina. This results in the retina becoming spongy, but the patient's vision is not seriously affected because the locations of the exudates are far away from the fovea.

2.1 Clinically significant maculopathy(CSME):

In this stage, most of the retinal blood vessels are damaged and the leakage area becomes bigger. The exudates leak out and deposit very close to the fovea. Hence, the visibility is greatly affected since images cannot properly be focused on the macula. Figure 3(c) shows the CSME fundus image. Most studies about diabetic maculopathy and associate risk factors are hospital-based cohort studies. There is only one population based cohort studies which was extended to a longitudinal study. Recent data have shown that better glycemic and blood pressure control are beneficial in reducing the incidence of macular edema. The quantification of diabetic maculopathy and detection of exudates on fundus images were studied. Global and local thresh holding values were used to segment exudates from the red-free images. Before thresh holding can be done, the digitized color photographs were preprocessed to eliminate photographic non-uniformities (shade correction), and the contrast of the exudates was then enhanced. The lesion-based sensitivity of exudates identification technique was reported to be between 61% and 100 % (mean 87%).

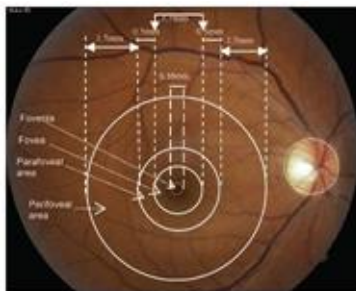


Figure 2. Normal fundus image showing the major vascular arcade.

The various levels or stages of diabetic eye diseases are reflected in the fundus images. Verification of this requires a skilled ophthalmologist, who can detect various features by looking at the fundus image. Fully automated methods to detect the severity of maculopathy can greatly help doctors in diagnosing diabetic eye diseases. Computerized detection is highly

useful in areas where experienced ophthalmologists are rarely available. Many investigations have been carried out on computer assisted analysis Automatic detection of micro aneurysms, hard exudates, cotton wool spots and hemorrhages for pathology detection was studied. Feature detection is necessary for identification and classification of the pathologies. There are many algorithms and techniques proposed to extract the features from fundus images.

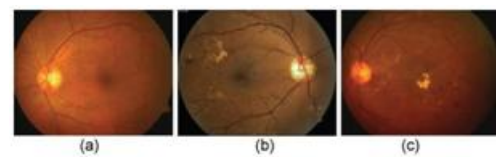


Figure 3. Fundus images: (a) normal, (b) non-clinically significant maculopathy and (c) clinically significant maculopathy

3 Data acquisition and processing:

In this work, about 124 retinal photographs of normal, clinically non-significant and clinically significant diabetic maculopathy were studied. The number and details of photographs in each group is shown in table 1. Images were stored in 24-bitJPEG format with an image size of 576x720 pixels. During the image acquisition process, a patient's chin is positioned on the chin rest and the patient is asked to look into the camera. The photographer aligns the digital system with the center of the patient's papillary axis. Figure 3 shows the fundus images of normal, non-clinically significant and clinically significant diabetic maculopathy.

TABLE I RANGE OF AGE, NUMBER OF SUBJECTS IN EACH GROUP

| Types | Normal | Moderate DR | Severe DR | Prolific DR |
|--------------------|--------|-------------|-----------|-------------|
| Age (years) | 32 ± 8 | 58 ± 13 | 45 ± 12 | 70 ± 10 |
| Number of subjects | 29 | 38 | 18 | 39 |

3.1. Local contrast enhancement:

The contrast of the fundus images tends to diminish as the distance of a pixel from the center of the image increased. The objective of preprocessing was to reduce this effect and to normalize the mean intensity. The intensities of the three color bands were transformed to an intensity-hue-saturation representation.

This allowed the intensity to be processed without affecting the perceived relative color values of the pixels. The contrast of the intensity was enhanced by a locally adaptive transformation. Consider sub-image, $W(i, j)$, of size $M \times M$ pixels, centered on a pixel located at (i, j) . Denote the mean and standard deviation of the intensity within $W(i, j)$ by μ_w and σ_w respectively. Suppose that f_{max} and f_{min} are the maximum and minimum intensities of the whole image. The adaptive local contrast enhancement transformation is defined by equations (1) and (2). Let the intensity, f , of the picture elements (pixels) of an $N \times N$ digital image be indexed by (i, j) $1 \leq i, j \leq N$. A sub-image of size $M \times M$ centered on (i, j) with $M \leq N$ is taken in this work. Denote the mean and standard deviation of the intensity within W by μ_w and $\sigma_w(f)$ respectively. The objective is to define a point transformation dependent on W such that the distribution is localized around the mean of the intensity and covers the entire intensity range. The implicit assumption is that W is large enough to contain a statistically representative distribution of the local variation of grey levels, yet small enough to be unaffected by the gradual change of contrast between the center and the periphery of the fundus image. The adaptive contrast enhancement transformation is defined by:

$$g(i, j) = 255 \frac{[\Psi_w(f) - \Psi_w(f_{min})]}{[\Psi_w(f_{max}) - \Psi_w(f_{min})]} \quad (1)$$

where the sigmoid function is given by:

$$y_w(f) = 1 + \exp \left(\frac{f - \mu_w}{\sigma_w} \right)^{-1} \quad (2)$$

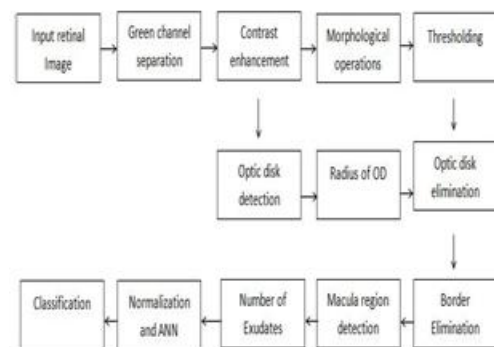
Where f_{max} and f_{min} are the maximum and minimum values of intensity within the whole image

$$\langle f \rangle_w = \frac{1}{M^2} \sum_{k,l \in W(i,j)} f(k,l) \text{ and}$$

$$\sigma_w^2(f) = \frac{1}{M^2} \sum_{k,l \in W(i,j)} [f(k,l) - \langle f \rangle_w]^2 \quad (3)$$

The local contrast enhancement function provides large contrast enhancement for an initially small s (poor contrast) and little contrast enhancement for an initially large s (high contrast). As a result of local contrast enhancement, the dark area is brighter and clearer showing more detail. However, the technique of local contrast enhancement not only adjusts the contrast of the image but also increases the noise. Hence, a 2D Gaussian smoothing filter or median filter has been applied in order to reduce the noise before the local contrast enhancement process.

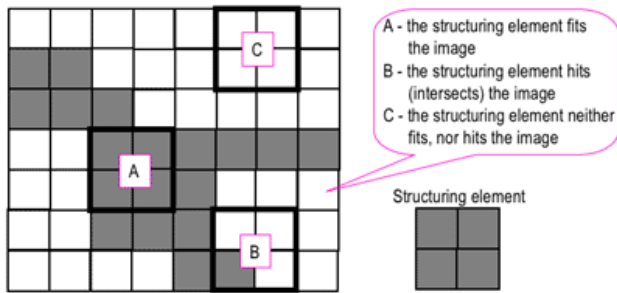
3.2 Block Diagram:



3.3 Morphological process:

Binary images may contain numerous imperfections. In particular, the binary regions produced by simple thresholding are distorted by noise and texture. Morphological image processing pursues the goals of removing these imperfections by accounting for the form and structure of the image. These techniques can be extended to grey scale images. Morphological image processing is a collection of non-linear operations related to the shape or morphology of features in an image. Morphological operations rely only on the relative ordering of pixel values, not on their numerical values, and therefore are especially suited to the processing of binary images. Morphological operations can also be applied to grey scale images such that their light transfer functions are unknown and therefore their absolute pixel values are of no or minor interest. Morphological techniques probe an image with a small shape or template called a structuring element.

The structuring element is positioned at all possible locations in the image and it is compared with the corresponding neighborhood of pixels. Some operations test whether the element "fits" within the neighborhood, while others test whether it "hits" or intersects the neighborhood.



Morphological process:

A morphological operation on a binary image creates a new binary image in which the pixel has a non-zero value only if the test is successful at that location in the input image. The structuring element is a small binary image, i.e. a small matrix of pixels, each with a value of zero or one.

4. Detection of optic disc:

The optic disc appears in the fundus image as a yellowish region. It usually occupies approximately one seventh of the entire image, 80x80 pixels. The appearance was characterized by a relatively rapid variation in intensity because the 'dark' blood vessels are beside the 'bright' nerve fibers. The variance of intensity of adjacent pixels was used for recognition of the optic disc. Consider a sub-image $W(i,j)$ of dimensions $M \times M$ centred on pixel (i, j) . Let $hfiw(i, j)$ as defined by equation (A3)

$$\langle f \rangle_w(i, j) = \frac{1}{M} \sum_{k,l \in W(i, j)} f(k,l)$$

be the mean intensity within $W(i, j)$. (If $W(i, j)$ extends beyond the image, then undefined intensities are set to zero and the normalization factor is correspondingly reduced.) A variance image was formed by the transformation

$$g(i, j) \rightarrow p(i, j) = \langle f^2 \rangle_w - (\langle f \rangle_w)^2$$

Where the sub image was 80x80 pixels. An image of the average variance within sub images was then obtained $asp(i, j) \rightarrow q(i, j) = p \setminus W(i, j)$ The location of the maximum of this image was taken the center of the optic disc, (id, jd) .

4.1 Hough Transformation:

The Hough transform is a feature extraction technique used in image analysis, computer vision, and digital image processing. The purpose of the technique is to find imperfect instances of objects within a certain class of shapes by a voting procedure. This voting procedure is carried out in a parameter space, from which object candidates are obtained as local maxima in a so-called accumulator space that is explicitly constructed by the algorithm for computing the Hough transform.

Circle detection process:

The process of identifying possible circular objects in Hough space is relatively simple,

- First we create our accumulator space which is made up of a cell for each pixel, initially each of these will be set to 0.
- For each (edge point in image (i, j)): Increment all cells which according to the equation of a circle $((i-a)^2 + (j-b)^2 = r^2)$ could be the center of a circle, these cells are represented by the letter 'a' in the equation.
- For all possible value of a found in the previous step, find all possible values of b which satisfy the equation.
- Search for the local maxima cells, these are any cells whose value is greater than every other cell in its neighborhood. These cells are the one with the highest probability of being the location of the circle(s) we are trying to locate.

Note that in most problems we will know the radius of the circle we are trying to locate beforehand, however if this is not the case we can use a three-dimensional

accumulator space, this is much more computationally expensive. This method can also detect circles that are partially outside of the accumulator space if enough of its area is still present within it.

4.2 Detection of fovea:

The center of the fovea was usually located at a distance of approximately 2.5 times the diameter of the optic disc, from the center of the optic disc. It was the darkest area of the fundus image, with approximately the same intensity as the blood vessels. The fovea was first correlated to a template of intensities.

4.3 Detection of exudates:

The exudates are well contrasted compared to the background surrounding them and appear to be a bright pattern. They have irregular shapes and borders. Detection of exudates is a challenging job as other features in the image such as optic disc and blood vessels have higher grey level variation and brightness patterns than the exudates. The exudates appear with more contrast in the green channel. Morphological image processing techniques are used for the detection of exudates. Dilation and erosion are two basic operations in morphological image processing. Closing and opening operations are applied extensively for detecting the exudates. Exudates contribute to the defects in a diabetic maculopathy retina, and all stages of diabetic maculopathy have them. Therefore it is important to distinguish them from the noisy background of the retina image for visual diabetic retinopathy classification purposes. The algorithm developed uses a morphological operation to smooth the background, allowing exudates to be seen clearly. Two structuring elements (SE) are used:

- (i) octagon SE to remove the vessels from the image; and
- (ii) Discshaped SE to identify the exudates.

5. Artificial neural network classification:

An artificial neural network (ANN) is an information processing paradigm that is inspired by the way biological nervous systems, such as the brain, process

information. The key element of this paradigm is the novel structure of the information processing system. It is composed of a large number of highly interconnected processing elements (neurons) working in unison to solve specific problems. Data enters at the inputs and passes through the network, layer by layer, until it arrives at the outputs. During normal operation, i.e. when it acts as a classifier, there is no feedback between layers. Hence, it is termed a feed-forward neural network. If the nature of the classification is more complex, a three-layer feed-forward neural network with sigmoid activation function is more suitable. This sigmoid transfer function is a prerequisite for the use of the powerful back propagation learning algorithm. In the present case, the nature of boundary between different classes is not clearly known, and therefore the three-layer network with sigmoid activation function is chosen as the classifier. Figure 4 shows the three-layer feed-forward neural network used for the classification. During the training phase, the connection weights of the last two layers are modified according to the 'delta rule' of the back propagation algorithm. There are four input neurons, one hidden layer with five neurons and three output neurons. The output neuron will classify three classes as '100' for normal, '010' for CSME and '001' for non-CSME. The network is trained with given set of training data and later tested with remaining testing samples.

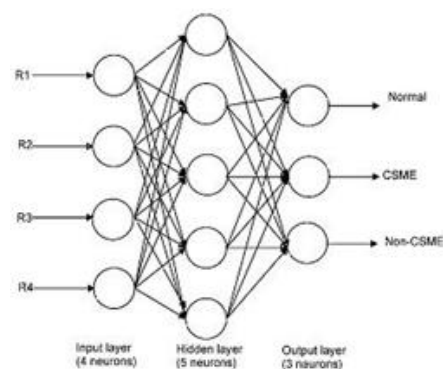


Figure 4

6. Edge Detection Techniques:

Edges are local changes in the image intensity. Edges typically occur on the boundary between two regions.

The main features can be extracted from the edges of an image. Edge detection has major feature for image analysis. These features are used by advanced computer vision algorithms. Edge detection is used for object detection which serves various applications like medical image processing, biometrics etc. Edge detection is an active area of research as it facilitates higher level image analysis. There are three different types of discontinuities in the grey level like point, line and edges. Spatial masks can be used to detect all the three types of discontinuities in an image. There are many edge detection techniques in the literature for image segmentation. The most commonly used discontinuity based edge detection techniques are reviewed in this section. Those techniques are Roberts's edge detection, Sobel Edge Detection, Kirsh edge detection, LoG edge detection and Canny Edge Detection.

6.1 Canny Edge Detection:

In industry, the canny edge detection technique is one of the standard edge detection techniques. It was first created by John Canny for his Master's thesis at MIT in 1983, and still outperforms many of the newer algorithms that have been developed. To find edges by separating noise from the image before find edges of image the Canny is a very important method. Canny method is a better method without disturbing the features of the edges in the image afterwards it applying the tendency to find the edges and the serious value for threshold. The algorithmic steps are as follows:

- Convolve image $f(r, c)$ with a Gaussian function to get smooth image $f^{\wedge}(r, c)$.

$$f^{\wedge}(r, c) = f(r, c) * G(r, c, \sigma)$$

- Apply first difference gradient operator to compute edge strength then edge magnitude and direction are obtain as before.

- Apply non-maximal or critical suppression to the

gradient magnitude.

- Apply threshold to the non-maximal suppression image.

Like Roberts and Sobel, the Canny operation is not very susceptible to noise. If the Canny detector worked well it would be superior.

The total number of white pixels, which indicate the exudates in each region, is the input data for the artificial neural network. Table 2 shows the ranges of the three parameters used to feed as input to the ANN. These features are subjected to the ANOVA (analysis of variance between groups) test to obtain the p-value. ANOVA uses variances to decide whether the means are different. This test uses the variation (variance) within the groups and translates into variation (i.e. differences) between the groups, taking into account how many subjects there are in the groups. If the observed differences are high then it is considered to be statistical significant. In our work, we have obtained p-values of less than 0.005, indicating that it is clinically significant. For the purpose of training and testing the classifier, a database of 350 patient samples is divided into two sets—a training set of 205 arbitrarily chosen samples and a test set of 145 samples. The training consisted of 5000 iterations.

TABLE II RANGE OF INPUT FEATURES TO ANN CLASSIFICATION MODEL

| Type | Perimeter of red layer | Perimeter of green layer | Perimeter of blue layer |
|------------------|------------------------|--------------------------|-------------------------|
| Normal | 13443 ± 1547.2 | 13240 ± 1618.1 | 31267 ± 11420 |
| moderate DR | 14077 ± 2183.3 | 13887 ± 2326.4 | 40346 ± 7811.6 |
| Severe DR | 23834 ± 6360.3 | 29047 ± 12435 | 37524 ± 6206.3 |
| Proliferative DR | 30268 ± 9810.2 | 30076 ± 11847 | 38053 ± 7069.8 |
| p-Value | <0.0001 | <0.0001 | 0.0003 |

7.Results and discussion:

The area covered by the exudates in the four regions (R1, R2, R3 and R4, as discussed in previous section) are considered as parameters for identifying the severity in the maculopathy images.

8. Conclusion:

Diabetic maculopathy is a complication of diabetes and a leading cause of blindness. It occurs when diabetes damages the tiny blood vessels inside the retina, the light-sensitive tissue at the back of the eye. An automatic system for identification of normal, non-CSME, and CSME retinal fundus image is proposed. The features are extracted from the raw images using image processing techniques and fed to a feed-forward neural network classifier for classification. We demonstrated an accuracy of more than 95% of correct classification, sensitivity of more than 95% and specificity of 100% for the classifier. The accuracy of the system can further be improved using proper input features (number of micro aneurysms and hemorrhaged areas), by using diverse quality of images for training and by increasing the size of the training dataset. To review the edge detection techniques which are based on discontinuity intensity levels, the relative performance of various edge detection techniques is carried out with an image by using MATLAB software. It is observed from the results LoG and Canny edge detectors produce almost same edge map. Canny result is superior one when compared to all for a selected image since different edge detections work better under different conditions. Even though, so many edge detection techniques are available in the literature, it is a challenging task to the research communities to detect the exact image without noise from the original image. Further scope can be done by using Support Vector as Classifier for detecting and classifying the Exudates.

References:

- 1) Dr. G. G. Rajput and Preethi N. Patil "Detection and classification of exudates using k-means clustering in color retinal images." 2014 Fifth International Conference on Signal and Image Processing.
- 2) Wei Bu, Xiangqian Wu, Xiang Chen, Baisheng Dai, YalinZheng "Hierarchical Detection of Hard Exudates in Color Retinal Images" Journal of Software, Vol 8, No 11 (2013), 2723-2732, Nov

2013doi:10.4304/jsw.8.11.2723- 2732

- 3) H. Li and O. Chutatape, "Automated feature extraction in color retinal images by a model based approach," IEEE Trans. on Medical Engineering, vol. 51, pp. 246-254, 2004
- 4) Nayak, J., P. S. Bhat, P.S., Acharya, U. R., "Automatic identification of diabetic maculopathy stages using fundus images", Journal of Medical Engineering & Technology.
- 5) Styles, Caroline J., Park, Serena J. K., McGhee, Charles N. J., Gamble, Greg, Donaldson, Mark L, "Evaluating the use of a scanning laser-derived oedema index to grade diabetic retinopathy and maculopathy", Clinical & Experimental Ophthalmology, Jan/Feb2007, Vol. 35 Issue 1, p18-23.
- 6) Peter, Jayanthi; Piantadosi, Julia; Piantadosi, Cynthia; Cooper, Peter; Gehling, Neil; Kaufmann, Claude; Goggin, Michael, "Use of real-time telemedicine in the detection of diabetic macular edema - a pilot study", Clinical & Experimental Ophthalmology, May/Jun2006, Vol. 34 Issue 4, p312-316.
- 7) Klais, Christina M. C.; Grupchev, Ivan D.; McGhee, Charles N. J.; Donaldson, Mark L., "Photostrening for diabetic retinopathy - a comparison of image quality between film photography and digital imaging", Clinical & Experimental Ophthalmology, Aug2004, Vol. 32 Issue 4, p393-396.
- 8) Tobin, K.W., Chaum, E., Govindasamy, V.P., Karnowski, T.P., "Detection of Anatomic Structures in Human Retinal Imagery", Medical Imaging, IEEE Transactions on Volume 26, Issue 12, Dec. 2007 Page(s):1729 – 1739.
- 9) Li, H.; Chutatape, O., "Fundus Image Features Extraction", Engineering in Medicine and Biology



Society, 2000. Proceedings of the 22nd Annual International Conference of the IEEE, Volume 4, 23-28 July 2000 Page(s):3071 – 3073.

10) Abdel-Razik Youssif, A.A.-H., Ghalwash, A.Z., Abdel-Rahman Ghoneim, A.A.S., “Optic Disc Detection From Normalized Digital Fundus Images by Means of a Vessels’ Direction Matched Filter”, Medical Imaging, IEEE Transactions on Volume 27, Issue 1, Jan. 2008 Page(s):11 – 18.