



## Detection and Classification of Exudates Using Morphological Processing & Artificial Neural Network in Color Retinal Images

**A Navya Sree,**  
M Tech Student,  
Department of ECE  
SVITS College, Mahaboobnagar

**B J Sunil, M Tech(Ph D),**  
Associate Professor & HoD  
Department of ECE  
SVITS College, Mahaboobnagar.

### ABSTRACT:

*Diabetic retinopathy is a kind of disorder which occurs due to high blood sugar level. This disorder affects retina in many ways. Blood vessels in the retina gets altered. Exudates are secreted, hemorrhages occur, swellings appear in the retina. Diabetic Retinopathy (DR) is the major cause of blindness. Automatic Recognition of DR lesions like Exudates, in digital fundus images can contribute to the diagnosis and screening of this disease. In this approach, an automatic and efficient method to detect the exudates is proposed. The real time retinal images are obtained from a nearby hospital. The retinal images are pre-processed via. Contrast Limited Adaptive Histogram Equalization (CLAHE). The preprocessed colour retinal images are segmented using K-Means Clustering technique. The segmented images establish a dataset of regions. To classify these segmented regions into Exudates and Non-Exudates, a set of features based on colour and texture are extracted. Classification is done using support Vector Machine This method appears promising as it can detect the very small areas of exudates.*

**Keywords** – Diabetic Retinopathy, Exudates, fundus image, k means clustering

### INTRODUCTION:

Diabetes is a group of metabolic diseases in which a person has high blood sugar either because the consistency does not make adequate insulin or because the cells do not respond to the insulin that is made.

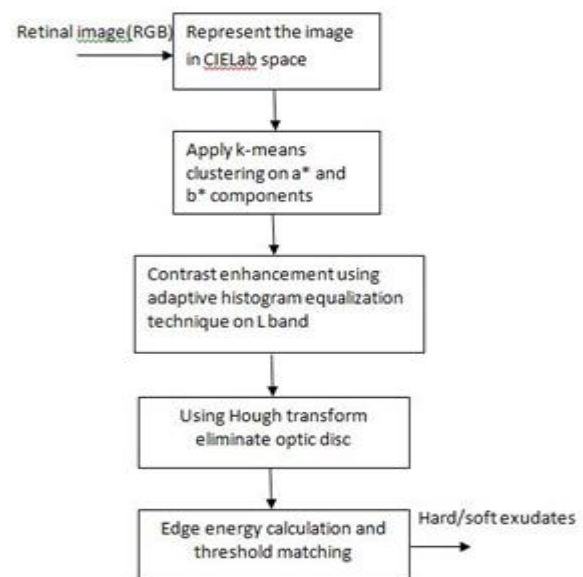
Diabetic related eye disease is a major cause of preventable blindness in the world. Diabetes can cause weakening in the body's blood vessels. It is a complication of diabetes, which can also affect various regions of the physical structure. When the diminished blood vessels have a high level of glucose in the retina, the sight will be obscured and can cause blindness eventual. This is known as Diabetic Retinopathy. Diabetic Retinopathy is one of the most common diabetic eye disease, which occurs when blood vessels in the retina changes. The blood vessels in the retina are very susceptible to dampening and can work through a series of modifications. When the blood vessels in the retina are damaged, these vessels swell and leak fluid. These modifications may be leaking or closure from the tiny blood vessels (known as capillaries) or the growth of weak, new capillaries that bleed very well. In some other cases, abnormal new blood vessels are grown on the surface of retina [3]. Diabetic Retinopathy is the most common diabetic eye disease which occurs due to damage of blood vessels in the retina and a leading cause of blindness in diabetic patients. Diabetic retinopathy is the main cause of blindness in America and over 99% countries. It is estimated to account for 12% of all the new cases of blindness in the United States each year. In Singapore, retinal disease accounts for more than half of the newly registered blindness with diabetic retinopathy as one of the primary contributors. It is calculated that approximately 10% of the population over the age of 40 are affected with diabetes and approximately 20% of this group will get some sort of diabetic complications in the optic. The symptoms of

Diabetic Retinopathy include blurred vision, sudden vision loss in one eye, seeing rings around lights, black spots. Diabetic Retinopathy usually affects both eyes. There are two cases of diabetes: Type 1 is insulin dependent and Type 2 non-insulin dependent diabetes. All people with diabetes, both Type 1 and Type 2 are at the risk of Diabetic Retinopathy. Generally, diabetic retinopathy is classified into two main phases, namely Non-Proliferative Diabetic Retinopathy (NPDR) and Proliferative Diabetes Retinopathy (PDR) [7]. NPDR is the earliest stage of Diabetic Retinopathy. With the damaged conditions in blood vessels the retina begins to leak extra fluid and low amount of blood into the eye. In NPDR lesions in the retina include microaneurysms (small red points), retinal hemorrhages (tiny spots of blood that leak into retina), hard exudates (deposits of cholesterol or other fatty tissues from the stock that have leaked), and intra-retinal micro vascular abnormalities. The bearing of these wounds in various degrees determines whether NPDR is mild NPDR, moderate NPDR or severe NPDR. PDR mainly occurs when many of the blood vessels in the retina close, preventing enough blood flow. In an effort to furnish blood to the area where the original vessels remain closed, the retina responds by forming new blood vessels which are called neovascularisation. PDR cause more serious vision loss than NPDR because it involves both central and peripheral vision. PDR results in neovascularisation of retina, vitreous hemorrhages, pre-retinal hemorrhages. The aim of the task is to create a system that detects hard exudates in a DR eye using fundus retinal images and form them as hard and weak exudates. Exudates are the elemental sign of Diabetic Retinopathy. If exudates are developed near the fundamental portion of your vision (macula), the central vision may be shortened. If the small retinal vessels close off (capillary closure or capillary drop out) the retina will become oxygen starved (ischemic). When this passes, white pieces of oxygen starved retina (cotton wool spots) may continue. This can contribute to the development of fresh blood vessels (neovascularization) which bleed and leak fluid easily. These vessels can result in scar tissue, which the

vitreous can pull. This can have bleeding into the vitreous and/or detach the retina. Automatic early detection of exudates in retina can assist ophthalmologists to prevent the spread of the disease more efficiently. Exudates are yellow spots seen in the retina. They are lipid break-down products that are left behind after localized edema resolves. Exudates are of two types, namely hard exudates(cotton wool spots) and soft exudates. Hard exudates are small, yellow in colour or white waxy patches. When hard exudates encroach on the macula, vision is affected. Hard exudates are detected through morphological image processing techniques which also eliminate the optic disc. The motivation behind this paper is that exudates are the primary visible sign of DR disease and are instantly related to retinal edema and visual loss, and also one of the most important retina lesions detectable in retinal images. The exudates identified using morphological methods are separated out as hard and weak exudates using fuzzy logic algorithm. The hard exudates extracted using a fuzzy logic algorithm uses values in RGB colour space of retinal images to form fuzzy sets and membership roles. The fuzzy output is computed for hard exudates according to the proportion of the expanse of hard exudates.

**PROPOSED METHOD**

The proposed method is outlined in the figure 1.



### A. Conversion from RGB color space to CIELAB color space

L\*AB color space is a perceptual model of human vision and an absolute reference space for color [14]. Working in LAB is counterintuitive at best. All the brightness information is in the L\* channel while color is encoded in the a\* and b\* channels. Preprocessing methods work more efficiently and effectively in LAB space. For example, noise removal from the image can be achieved by applying filters to either a\* channel or b\* channel without affecting the contrast which is stored in L\*channel. Therefore, in the proposed method we choose LAB color space over RGB color space.

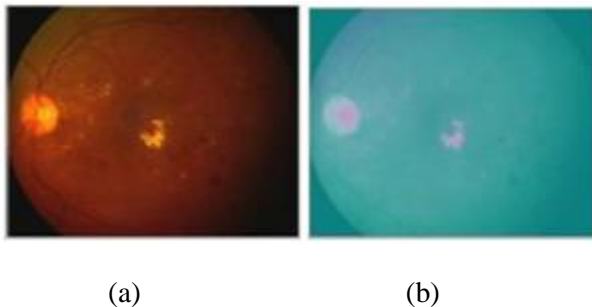


Figure 2.a. Original RGB Fundus Image b. CIELAB image

### B. K-mean Clustering

Because of the computational simplicity of the k-means algorithm over other clustering algorithms we decided to use the k-mean clustering in the proposed work. The k-mean clustering algorithm is a special case of the generalized hard clustering algorithms. It is applied when point representatives are used and the squared Euclidean Distance is adopted to measure the dissimilarities between vectors  $x_i$  and cluster representatives  $\theta_j$ . The k-means algorithm is given below.

#### Algorithm:

Step1: Choose arbitrary initial estimates  $\theta_j(0)$  for the  $\theta_j$ 's,  $j=1, \dots, m$ .

Step2: Repeat

1. For  $i=1$  to  $N$ 
  - o Determine the closest representative, say  $\theta_j$  for  $x_i$ .
  - o Set  $b(i)=j$ ;
- End {for}
2. For  $j=1$  to  $m$ 
  - o Parameter updating: Determine  $\theta_j$  as the mean of the vectors  $x_i \in X$  with  $b(i)=j$ .
- End {for}

Until no change in  $j$ 's occurs between two successive iterations.



Figure 3. Cluster labeled image

### C. Contrast Enhancement

Contrast enhancement leads to enhancement of separability between exudates (foreground) and background. As CIELAB color space is been used in the proposed method, we know that L\* channel contains all the information related to brightness. Adaptive histogram equalization technique is applied to this channel to facilitate enhancement of feature extraction

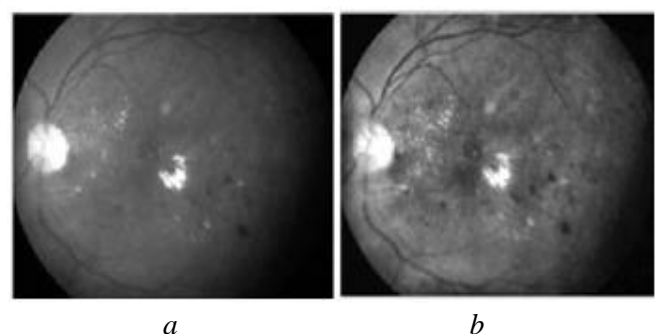


Figure 4. a. L channel Image b. Contrast enhanced image

**D. Blood Vessel Detection**

To facilitate exudates extraction from the pre-processed image, blood vessel network is detected and then eliminated from the image using morphological operations. Morphological operations can readily be used in medical image analysis as it supports powerful tools to extract pathologies based on shape [17]. The morphological operations used in the proposed work are given below.

1. Dilation:  $X \oplus B = \{z | [(\bar{B})_z \cap X] \subseteq X\}$
2. Erosion:  $X \ominus B = \{z | (B)_z \subseteq X\}$
3. Closing:  $X \cdot B = (X \oplus B) \ominus B$

An important part of applying morphological operations is to decide on the shape and size of structuring element. In the proposed work, a ball shaped structuring element of size 8, was found to be optimal for eliminating the blood vessel network from the retinal images of local data base.

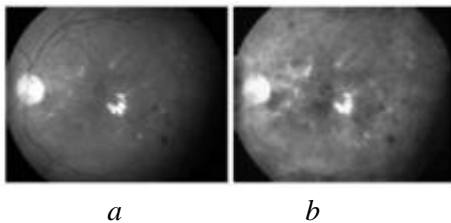


Figure 5. a. L channel image b. image after morphological operation

**E. Hough Transform for Circle**

FerouiAmel et al[3], used mathematical morphology and image reconstruction for removing the optic disk(OD). The technique empirically removes the OD but does not ensure that the correct part of the image is eliminated. Hence, we used Hough transform technique[16] to fit a circle to OD and ensure that the area located in the image is OD.

The Circular Hough Transform (CHT) relies on equations for circles. The equation of the a circle is,

$$r^2 = (x - a)^2 + (y - b)^2$$

Here a and b represent the coordinates for the center, and r is the radius of the circle. The parametric representation of this circle is

$$\begin{aligned} x &= a + r * \cos(\theta) \\ y &= b + r * \sin(\theta) \end{aligned}$$

Circular Hough Transform Algorithm works is presented below.

**Step1:** Covert color retinal image into grayscale

**Step2:** Create a 3D Hough array (accumulator) with the first two dimensions representing the coordinates of the circle origin and the third dimension represents the radii.

**Step3:** Perform edge detection using the Canny edge detector.For each edge pixel, increment the corresponding elements in the Hough array.

**Step4:** Collect candidate circles, and then delete similar circles.

**Step5:** Draw circles around the object.

In the proposed work, to assign the values for a and b, we first extract the portion of image that contain the optic disk. This is achieved by performing optic disk localization using correlation coefficient. Then, the size of the sub-image is assigned to a and b and radius is fixed to range between 45 to 55 pixels[15 ].

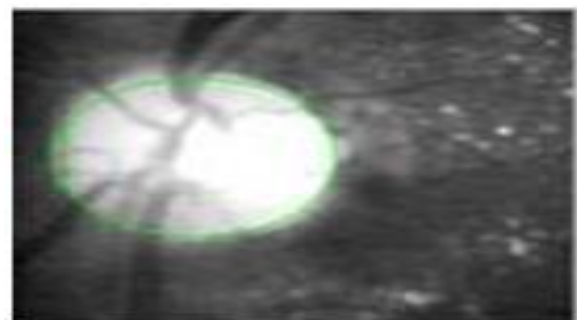


Figure 6. Optic disk marked using Hough Transform for circle

### F. Classifying Hard and Soft Exudates

The final step is to classify the exudates as hard and soft based on the threshold value and edge energy. Edge energy calculation is required to extract the exudates with sharp edges which are a characteristic feature of hard exudates. FerouiAmel et al [3], used Kirsch operator and green channel of RGB image to determine the edge energy. Kirsch operator requires more computational time and the results are not better than canny operator. Hence, we preferred canny operator over Kirsch operator for edge energy detection. The hard exudates are extracted by combining this edge energy and a threshold value. To extract the soft exudates subtract the hard exudates image from the image that contains both types of exudates.

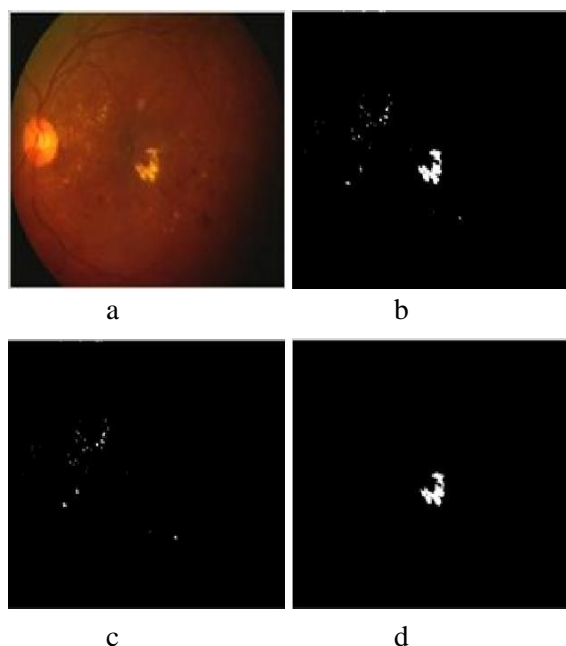


Figure 7.a. Original RGB image b. binary image with Exudates c. Binary image with only HE d. Binary image with only CWS

### EXPERIMENTAL RESULTS

The proposed method is experimented on 100 images collected from Karnataka institute of Diabetology, Bangalore. All the images have a full visible optic disk. For these images, using Hough transform technique, OD has been eliminated with an accuracy of

100%. However, the method fails for the images that have only a portion of optic disk [ Fig. 8.e ], The morphological operations for removing the blood vessel network have yielded 100% results. Lastly, the exudates have been classified as hard and soft exudates successfully based on edge energy and threshold value.

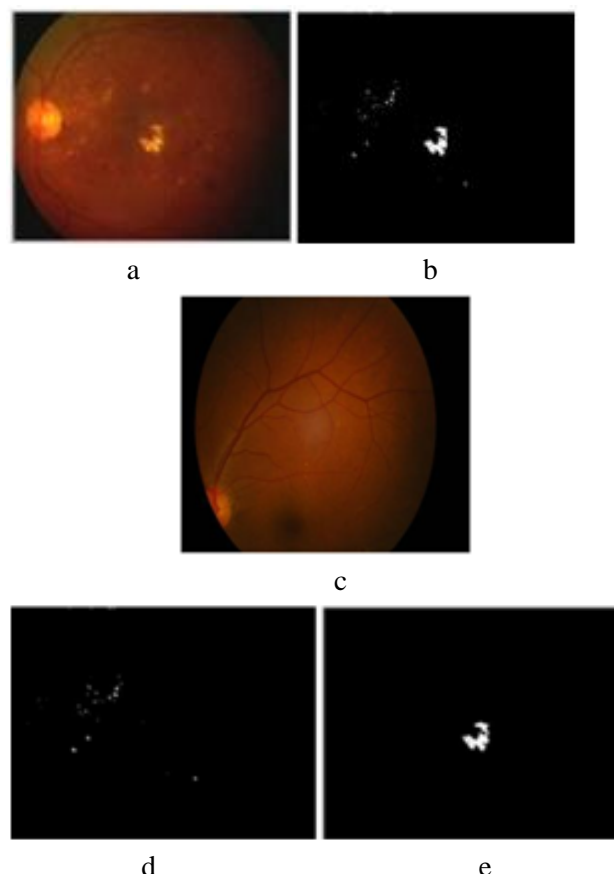


Figure 8.a. Original RGB image b. binary image with Exudates c. Binary image with only HE d. Binary image with only CWS, e. partial optic Disk

### CONCLUSION

Automatic detection and classification of exudates using k-means clustering algorithm has been presented in this paper. The proposed method has yielded encouraging result. The proposed method has successfully classified the exudates as hard and soft exudates. The method successfully detects the exudates for retinal images wherein OD is visible completely. However, the method fails to identify the OD in case of retinal images where OD is partial

visible. Comparing the results with the method presented in [3], the proposed method classifies the exudates as soft and hard as to identifying only hard exudates. Such classification helps the ophthalmologists in diagnosing the retinal diseases.

## REFERENCES

- [1] [www.Diabetesjournal.org](http://www.Diabetesjournal.org).
- [2] [www.nihseniorhealth.gov](http://www.nihseniorhealth.gov).
- [3] FerouiAmel et al, "Improvement of the hard exudates detection method used for computer – aided diagnosis of diabetic retinopathy", I.J.Image, Graphics and Signal Processing, DOI: 10.5815/ijjgsp.2012.04.03.
- [4] H. Li and O. Chutatape, "Automated feature extraction in color retinal images by a model based approach," IEEE Trans. on Medical Engineering, vol. 51, pp. 246-254, 2004
- [5] C. I. Sanchez, M. Garcia, A. Mayo, M. Lopez and R. Hornero, "Retinal image analysis based on mixture models to detect hard exudates," Medical Image Analysis, vol. 13, pp. 650-658, 2009.
- [6] M. Garcia, C. I. Sanchez, M. I. Lopez, D. Abasolo and R. Hornero, "Neural network based detection of hard exudates in retinal images," Computer Methods and Programs in Biomedicine, vol. 93, pp. 9-19, 2009
- [7] AkaraSopharak and BunyaritUyyanonvara proposed an "Automatic exudates detection on thai diabetic retinopathy patients retinal images" Proceedings of the 2006 ECTI International Conference, pp.709-712; May (2006)
- [8] AshagowdaKaregowda, AsfiyaNasiha, M.A. Jayaram and A.S. Manjunath proposed an "Exudates detection in retinal image using back propagation neural network" International Journal of Computer Applications (0975 – 8887) Volume 25– No.3, July 2011
- [9] AkaraSopharak, BunyaritUyyanonvara, Sarah Barman and Thomas Williamson "Automatic detection of diabetic retinopathy exudates from non-dilated retinal images using mathematical morphology methods" Computerized Medical Imaging and Graphics 32 (2008) 720–727
- [10] AkaraSopharak, BunyaritUyyanonvara, Sarah Barman proposed an "Automatic exudates detection for diabetic retinopathy screening" doi:10.2306/scienceasia1513-1874.2009.35.080
- [11] Kittipolwisaing, NualsawatHiranskolwong and EkkaratPothiruk proposed an "Automatic optic disc detection form low contrast retinal images" Applied Mathematical Sciences, Vol. 6, 2012, no. 103, 5127 – 5136
- [12] Siddalingaswamy P. C. and GopalakrishnaPrabhu. K proposed "Automatic Localization and Boundary Detection of Optic Disc Using Implicit Active Contours". 2010 International Journal of Computer Applications (0975 – 8887) Volume 1 – No. 7
- [13] ViraneeThongnuch and BunyaritUyyanonvara proposed "Automatic optic disc detection from low contrast retinal image of ROP infant usinf GVF snake" Suranaree J. Sci. Technol. Vol. 14 No. 3; July-September 2007
- [14] JaspreetKaur, Dr H. P. Sinha proposed "Automated Localization of Optic Disc and Macula from fundus Images" , International Journal of Advanced Research in Computer Science and Software Engineering, ISSN – 2277128X, Volume 2, issue 4, April 2012.
- [15] G. Eason, B. Noble, and I. N. Sneddon, "On certain integrals of <http://www.egr.msu.edu/classes/ece480/capstone/a>



1110/group03/ece480\_dt3\_application\_note\_dembe  
1 ef.pdf

- [16] Rafael C. Gonzalez, Richard Eugene Woods, Steven L. Eddins “Digital image processing using matlab” Pearson Education India.
- [17] S. Jayaraman, S. Esakkirajan, T. Veerakumar, “ Digital image processing”, Tata McGraw-Hill Education.